

IABPA News
Vol 14 #2 June
1998 pp 6-8
Proj. Bloodstains

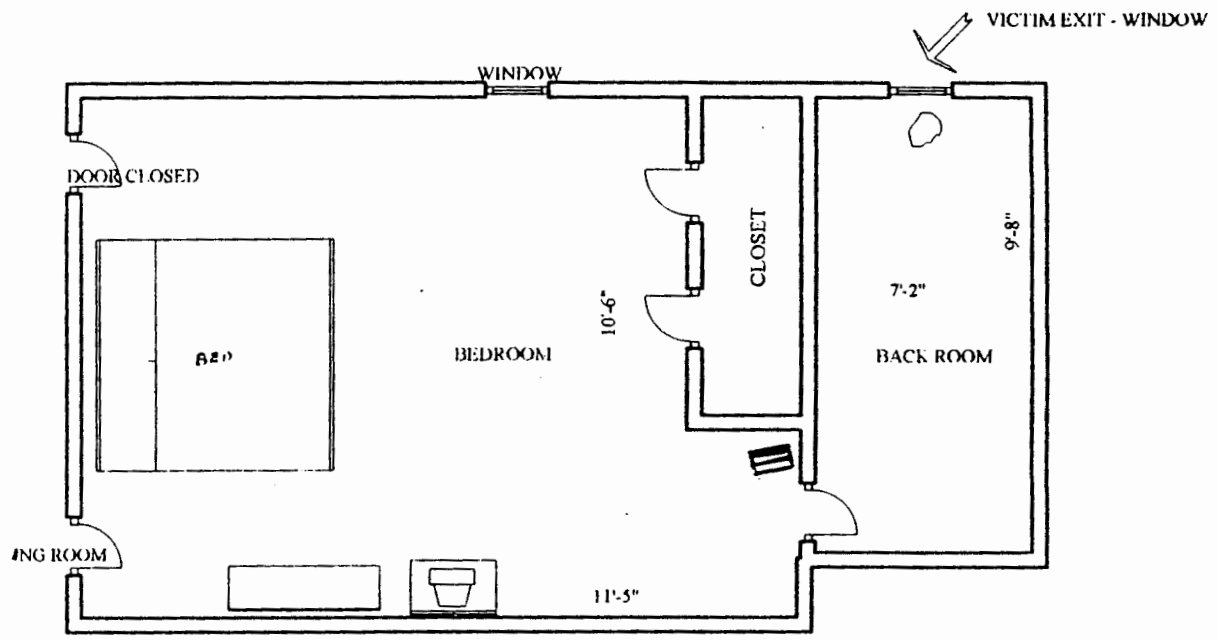
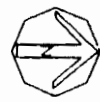INTERMITTANT PROJECTED BLOODSTAINS

by Senior Special Agent David Barnes
Crime Scene Unit
Ohio Bureau of Criminal Identification and Investigation

When all of us were taught the basics of bloodstain pattern investigation, we learned the concept of projected bloodstains, which occurs typically when blood exits a breached artery in a column with each pulse of the heart. This column quickly breaks up over distance into individual large segments which create the well known groups of large spatters with secondary spatters and/or downward drips on vertical surfaces upon impact. We also learn that, depending of the size of the artery and the location of the wound beneath overlying tissue, the exiting blood may be difused much like a nozzle on a hose, making the recognition of this classification of spatter more difficult. There may be the occational case, however, when the wound is so deep that despite the power of the source, in this case the left side of the heart, that the phenomom of projected blood will only occur when the victim stuggles in a certain manner. The case that follows is an example.

In August of 1997, our agency was requested to process a homicide scene at a small one storey home in a small village. A female juvenile overnight guest had sought protection from the sexual advances of a male adult overnight guest in the bedroom of the homeowner. The enraged male guest burst nude into the bedroom, jumped onto the bed when the homeowner lay, and began stabbing him with a kitchen carving knife with a five inch blade. The juvenile was unhurt. The suspect then left the bedroom, calmly got dressed, and left the premises through the front door. In the meantime, the victim was deperately struggling to escape what he though was still an imminent threat to his life. Drip cast off spatters indicated that he left the bed, and went northbound to a doorway between the bedroom and a back room. A baby gate was in place here, in order to contain a doberman puppy in the room. After removing the gate from the doorway, he proceeded to the single window in the room, raised the sash, broke out the screen, exited the window, and proceeded 139 feet to the front walk of the house next door, where he collapsed, and was found by rescue personel. An examination for various types of bloodstain patterns at the scene showed apparent projected blood in only three locations: on the baby gate, on the west doorframe to the back room at a height of 13 inches, and on the sill of the opened window, both on top and on the outside edge. This raised a question in my mind in light of the distance traveled by the victim. This unease continued at the autopsy, during which pathologist failed to find any sign of a breached artery. Finally, at the latter stages of the examination, a small puncture was found near the apex of the heart into the left ventricle.. This occured as a result of a stab wound to the chest. Thus a source of the projected blood had been found, and it was the most powerful of any possible source in the body. The pathologist informed me that because of the location of the puncture, the blood would have to travel though three muscle layers to leave the body.

The start and stop nature of the projected bloodstains found at the scene had been accounted for. The blood only had an opportunity to leave the body where the victim had acted in a certain manner, such as raising his arms to remove the baby gate, raise the window sash, or pull himself through the window. The lesson that we all take from such cases is that certain types of wounds can produce bloodstain phenomena that we are not used to seeing.



97-21452
CS-74-97-01-1155
HOMICIDE
08-22-97

206 EAST EUCLID STREET
NOT TO SCALE